

Palatine suture obliteration method for age estimates of burn victims with minimal tooth remains: a case report

by Institut Ilmu Kesehatan Bhakti Wiyata Kediri

Submission date: 18-Sep-2025 06:37PM (UTC+0700)

Submission ID: 2212931324

File name: Lektor_1_Scopus_Q3_-_Eko_Prastyo.pdf (848K)

Word count: 4666

Character count: 23988


See discussions, stats, and author profiles for this publication at: <https://www.researchgate.net/publication/392329732>

Dental Journal Palatine suture obliteration method for age estimates of burn victims with minimal tooth remains: a case report


Article in Dental Journal (Majalah Kedokteran Gigi) · June 2025
DOI: 10.20473/djmg.v4i3.p299-300

CITATION
1

10 authors, including:




Eko Prastyo
Institut Ilmu Kesehatan Bhakti Wiyata
20 PUBLICATIONS 14 CITATIONS
[SEE PROFILE](#)




Roben Suhadi Pasaribu
9 PUBLICATIONS 25 CITATIONS
[SEE PROFILE](#)

READS
55



Elza Ibrahim Auerkari
University of Indonesia
289 PUBLICATIONS 1,102 CITATIONS
[SEE PROFILE](#)



Nurtami Soedarsono
University of Indonesia
65 PUBLICATIONS 310 CITATIONS
[SEE PROFILE](#)

Case report

Palatine suture obliteration method for age estimates of burn victims with minimal tooth remains: a case report

Eko Prastyo^{1,2}, Fitri Ambar Sari³, Elza Ibrahim Auerkari¹, A. Winoto Suhartono¹, Roben Suhadi Pasaribu⁴, Nurtami Soedarsono¹, Dieci Zevrianty³, Aditia Dedek Yunus⁴, Pertti Auerkari⁵

¹Forensic Odontology Specialist Study Program, Department of Oral Biology, Faculty of Dentistry, Universitas Indonesia, Jakarta, Indonesia

²Department of Forensic Odontology & Medicolegal, Faculty of Dentistry, Institut Ilmu Kesehatan Bhakti Wiyata, Kediri, Indonesia

³Department of Forensic Medicine and Medicolegal Studies, Faculty of Medicine, Universitas Indonesia, Jakarta, Indonesia

⁴Master of Dental Sciences - Forensic Odontology Specialization, Faculty of Dentistry, Universitas Indonesia, Jakarta, Indonesia

⁵Department of Mechanical Engineering, School of Engineering, Aalto University, Espoo, Finland

ABSTRACT

Background: A disaster is a serious disruption in the functioning of a society that can cause many losses. It can be caused by nature or humans. When the loss of life is on a large scale, the recovery process is made more complicated by simultaneous identification operations. Biological profiling is of paramount importance when investigating cases; the age at which a victim dies is crucial for reconstructing the victim's life. **Purpose:** The purpose of this case study is to highlight the utility of palatal suture obliteration as a valuable indicator for age estimation in adults, especially when there are minimal remaining dental elements that make age estimation by other methods of dental analysis impossible. **Case:** The author presents a case of burn victims due to a fire disaster in the fuel oil terminal area in Jakarta that killed several victims. As they were found in a visually unrecognizable condition, without identity documents, and in a state where the victims' teeth left few dental elements, effort is needed to assist in identifying the victims, including victim age estimation techniques with ideal methods that can be applied in the field. **Case management:** The Crow-Glassman Scale (CGS) is used to describe the extent of burns to tissue remnants. On external examination, all body parts showed the burns reaching level 3 CGS. The victim is estimated to be over 50 years old. Decision making is based on the guidelines of the Mann method, where if more than 50% of the anterior median palatine suture is obliterated, then the minimum estimated age is 50 years. **Conclusion:** The obliteration of the palatal sutures can be used as supporting evidence when considered alongside other more reliable age indicators that can narrow down the age of unidentified individuals.

Keywords: age estimation; burn victim; Mann method; palatine suture obliteration

Article history: Received 13 February 2024; Revised 14 June 2024; Accepted 15 July 2024; Online 28 May 2025

Correspondence: Elza Ibrahim Auerkari, Department of Oral Biology, Faculty of Dentistry, Universitas Indonesia, Salemba Raya No. 4, Jakarta 10430, Indonesia. Email: eaurkari@yahoo.com

INTRODUCTION

The term "disaster" refers to any major breakdown in the functioning of communities/societies, resulting in widespread human, material, economic and/or environmental loss, which exceeds the capacity of the affected communities/societies to respond. It can be caused by nature or humans.^{1,2} When there is a large loss of life, the recovery process is complicated by simultaneous identification operations.³ The identification of the victims of a disaster is seen as an important sign of respect, not only for the deceased, but also for the families of

the deceased. Disaster victim identification can also be required for various legal matters, such as assisting criminal trial proceedings, facilitating inheritance settlements, or establishing the right of a widowed spouse to remarry. Thus, a special process is needed to facilitate positive identification of the deceased.¹

Regardless of the type or scale of the disaster, several forces act on the body. As a result, victims may be found with intact or early intact bodies; recognizable or unrecognizable body parts; soft tissue masses; isolated, complete, or traumatized bones (with or without varying degrees of burnt and/or decayed soft tissue);

small undiagnosed bone fragments; or a combination of these.^{2,3}

When a body is found, one of the first investigative priorities is to identify the victim; without this information, the case would not progress. Identification begins with biological profiling, where the age at death plays a key role in reconstructing victims.^{4,5} Upon reaching adulthood, methods for estimating age are primarily based on degenerative changes of the skeleton. Observed skeletal features can define different stages or phases, and these are indicators of biological age.⁶ Adult skeletal changes are a function of degenerative processes influenced by extrinsic factors such as biomechanical loading, diet, and health status. Estimating the age of adult victims in the context of forensic investigations should follow a general protocol involving 1) a thorough assessment of degenerative changes throughout the skeletal system, 2) an evaluation of all available skeletal elements using the most appropriate technique, and 3) a probabilistic estimation of the age at which the person died.²²

Obliteration of the palatine suture can be a valuable indicator for age estimates of adults, especially if there are minimal remaining dental elements that make it impossible to estimate age by other methods of dental analysis.^{6,7} In a study conducted by Mann et al.,⁸ age estimation using palatine suture has a 34% reliability in male individuals. Nonetheless, palatine suture has been shown to be beneficial for individuals whose age ranges between 60 and 80 years.⁹

The human hard palate develops from the intra-membranous nasomaxillary complex and is formed by two lateral processes growing toward the midline and anterior portion known as the primary palate. It also consists of three pairs of bones joined along the midline by midpalatal sutures. It is divided into the premaxillary, maxillary, and palatine segments. In addition, the midpalatal suture undergoes progressive morphological changes until adulthood.¹⁰

In the lingual aspect, the palate disappears with age. Mann (1987)¹¹ were the first formal investigators of palatine suture fusion in a small sample of Tennessee natives. Mann et al.⁸ measured the number of obliterations along the four sutures (incisive suture [IN], posterior median palatine suture [PMP], transverse palatine suture [TP], and anterior median palatine suture [AMP]) using a five-point scale ranging from 0 to 4. They report a common pattern that is useful for age estimation, although the number of obliterations varies between individuals.⁸ Mann et al.⁸ did not establish a formal age range for the fusion of the sutures, but they did report the earliest age of fusion at each site. Thus, an individual's age is estimated from the suture with the oldest age.⁸ The appearance of dotted lines on some sutures cannot be explained, and a visual observation of the amount of suture fusion is believed to be better than caliper measurement.

A recent study revised the results of Mann et al.⁸ and examined the transverse suture at two locations, along the

midline and near the palatine foramen major. As a result, five regions were observed along the other four sutures. The study concludes that a lack of suture coverage does not necessarily indicate a younger individual.⁸ Rather, the presence of obliteration is indicative of increasing age. Importantly, some older individuals may show delayed fusion of the palatal suture, even into the eighth decade of life, but the general pattern of erasure is useful to estimate the age at death.¹³ New developments—for example, CT scans—have allowed for a more accurate assessment of craniofacial morphological structures, such as midpalatal sutures.¹⁴

In this case report, the author presents a case of burn victims due to a fire disaster in the fuel oil terminal area in Jakarta that killed a number of victims. They were found in a visually unrecognizable condition and without identity documents. In addition, the condition of the victims' teeth left few dental elements, so effort is needed to assist in identifying victims, including victim age estimation techniques with ideal methods that can be applied in the field. This case report aims to highlight the utility of palatine suture obliteration as a valuable indicator for age estimation in adults, especially when there are minimal remaining dental elements that make age estimation by other methods of dental analysis impossible.

CASE

A large fire occurred in the North Jakarta Fuel Oil Terminal (TBBM) area on Friday, March 3, 2023, at 8.00 p.m. The fire caused panic among the residents because the location was close to a densely populated neighborhood. It started when residents smelled a strong smell of fuel oil (BBM) before an explosion was heard and flames appeared, causing smoke to rise. It was later discovered that the incident began with the burning of fuel oil pipelines. At 8:11 p.m., the firefighters received a case report. Initially, the firefighters only deployed two units of fire trucks and 10 personnel, which then increased to 52 units of fire trucks and 260 personnel. At 8:22 p.m. the firefighters began to extinguish the fire and help victims. The fire was successfully extinguished on Saturday, March 4, 2023, at 02.00 a.m. Several people died from this terrible fire.

Some of the victims' bodies were sent to the mortuary of the Forensic Science & Medicolegal Department of Dr. Cipto Mangunkusumo Hospital for external examination and dental autopsy, one of which is presented in this report. External examinations such as body bruising, body stiffness, and body temperature were no longer useful in providing an accurate estimate of the time since death. The corpse's condition showed a pugilistic demeanor with the headgear free of any soft tissue, but it was not calcified. Although the head was present, most of the flesh was absent as the soft tissues of the face had been burnt away, rendering visual identification impossible. The brain was

burnt and had a dry, rubbery, brittle consistency. The eyes, nose, and ears could not be assessed. In the forearm, there are lever bones and cubit bones, as well as the bones of the fingers of the right hand. Multiple bones of the head, neck and torso were broken, while both upper limbs and lower limbs remained intact.

CASE MANAGEMENT

The Crow-Glassman Scale (CGS) is used to describe the extent of burns to tissue remnants. On external examination, all body parts showed the burns reaching level 3 CGS (Figures 1 and 2). Skin and nutrition cannot be assessed. The body's length was 150 cm, while its weight was not calculated. The cavities of the body's parts became visible with the internal organs open. External male genitalia can still be seen, so sex determination was easily established. No identifications were found, and the object beside the body contained asbestos cut. The victim's age was unknown. The results of the dental examination are presented in Table 1. The results of the dental autopsy examination

revealed conditions of victim's oral cavity as depicted in Figures 3 and 4.

In burn victims, a toxicology examination based on the level of CO in hemoglobin should be carried out to determine the vitality of the victim at the time of burning.

Table 1. Dental examination result of Mr. X (victim of fuel terminal fire)

11	mpm	rrx	21
12	rrx	rrx	22
13	rrx	att	23
14	mpm	rrx	24
15	sou	att	25
16	att	att	26
17	att	att	27
18	non	non	28
48	non	non	38
47	M car, att	MOD car, att	37
46	O car, att	MOD car, att	36
45	att	O car, att	35
44	att	O car, att	34
43	att	att	33
42	rrx	att	32
41	mpm	mpm	31



Figure 1. Condition of burn victim's body with CGS level 3.




Figure 2. Condition of the tissue around burnt mouth; (A) visible from the right side, (B) visible from the front, (C) visible from the left side. The teeth are exposed (blue arrows), and part of the mandible bone is also exposed (green arrow).

Most of the deaths were caused by carbon monoxide poisoning and fatal thermal injuries from the fires.¹⁵

The recovery of burnt remains, which are often very fragment¹³ and fragile, requires special consideration. Extreme heat can change the size, color, shape, and mechanical properties of human tissue, which can make the rest of the body difficult to recognize.¹

The precise determination of adult age at death is essential for the description of osteology populations. Most of these methods are based on morphological and degenerative changes in the human skeleton that occur with age. Palatal suture obliteration is one of these age estimation techniques. This method was first introduced in 1987 and then revised in 1991 by Mann et al.^{8,11}

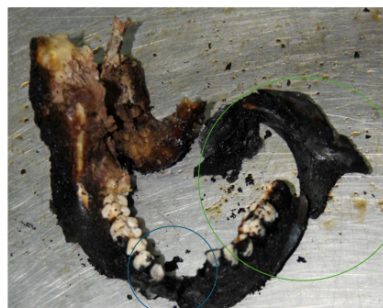

Figure 3. A ramus mandibular fracture (green circle) and symphysis mandibular fracture (blue circle) were found.

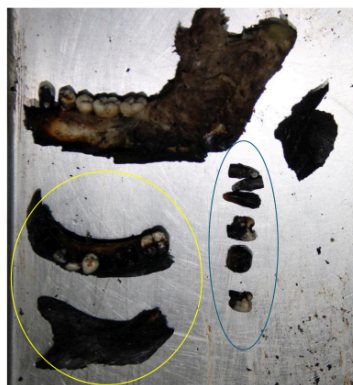

Figure 4. A mandibular fracture (yellow circle) was found, and a tooth was removed from the socket (blue circle).

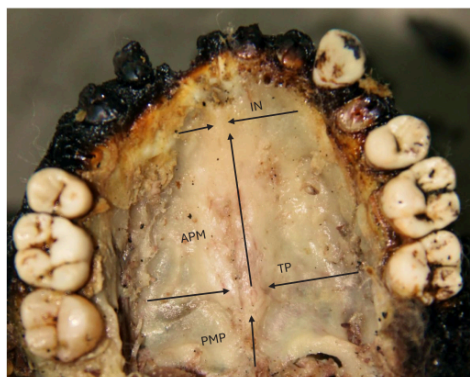


Figure 5. The arrows indicate the obliteration of the victim's palatine sutures (IN: Incisive Suture; APM: Anterior Median Palatine Suture; TP: Transverse Palatine Suture; PMP: Posterior Median Palatine Suture).

METODE MANN (MANN'S METHOD)

1. Incisive suture (IN) obliterated --> minimum 20th (20-24 th)
2. Posterior Median Palatine Suture (PMP) obliterated --> minimum 29 th
3. Transverse Palatine Suture (TP) obliterated --> minimum 30 th
 - a. TP obliterated < 50% --> 30-40 th
 - b. TP obliterated > 50% --> minimum 41 th
4. Anterior Median Palatine Suture (AMP) not obliterated --> < 50 th
5. TP + IN + PMP completely obliterated + 1mm or more AMP suture obliterated --> minimum 50th
6. AMP obliterated > 50% --> minimum 50 th

Figure 6. The basic steps for making age estimation is through observing the obliteration of palatine sutures by the Mann method.⁸

of obliteration of the palatal suture and associating it with the estimated age.⁴ As a result, the victim in this case report is estimated to be over 50 years old. Decision making is based on the guidelines of the Mann method (Figure 6),⁸ wherein if APM has been obliterated by more than 50%, one can estimate that the minimum age is 50 years old.

DISCUSSION

The method used to estimate age should meet the following criteria: (i) It must have been the subject of peer-reviewed publications in the scientific community, (ii) its accuracy must be tested using valid statistical methods and clearly described, and (iii) the method must be sufficiently precise for routine use in forensics. Current methods of estimating age at death can be divided into those based on skeletal and dental growth and those based on degenerative changes. In adults, skeletal and dental development is complete, making age estimation more difficult than in subadults.⁹

The loss of the palatal suture is progressive and age-related. A general pattern of closure has been found, beginning in adolescence, and ending in the 50s of life. The obliterations that occur follow a specific direction and sequence according to Mann et al.⁸ The suture follows a general pattern of obliteration with the IN being the first to experience obliteration (at approximately age 20 on average or before adulthood), followed by the PMP, then the TP, and finally, the AMP (at approximately age 54 on average and showing evidence of complete closure in the sixth decade of life). The developmental path of closure is centripetal (from lateral to median). The IN and the TP start to close from the lateral side and continue to the midline of the maxilla. Age estimation is based on the last suture showing obliteration. Some studies have suggested that gender should be a consideration in the use of this feature for age estimation purposes.^{8,16}

In this case report, we use the Mann method. We use this method because, in this case, the victim had suffered a severe burn that drastically damaged his body structure, including his teeth and jaw. However, the condition of the palate was still well preserved. This is the main reason for using this method, as the palate is a parameter used in

the Mann method.⁸ According to the Mann method,⁸ the victim in this case has reached stage 5, as all four sutures (IN, PMP, TP, and AMP) are fully closed. The victim's age is estimated to be over 50 years old.⁸

Beauthier et al.¹⁷ recently performed age-related studies on a sample of French and Belgian individuals using the palatine suture. Beauthier et al.¹⁷ developed a completely new segmented method for the recording of the palatal suture by dividing the palate into 15 sub-sections with five stages of fusion. The authors concluded that palatal suture obliteration develops with age and is comparable to vaulting. They also confirmed the progression of segmented and directed palatal suture obliteration (i.e., obliteration progresses from lateral to median and from posterior to anterior). Specifically, the center of the transverse palate is defined as the length of sutures along the transverse plane ending at the beginning of the palatal curvature into the alveolus. The transverse foramen follows the suture from the palatal curve to the greater palatal foramen bilaterally. The middle anterior palate runs from the junction with the transverse suture of the anterior palate to the foramen incisivum. The results confirmed that the fusion of the palatal sutures is not slow, and in some cases, the sutures never dissolve, which results in an extremely high durability.¹³

There are complex biomechanical and genetic influences on craniofacial and palatal suture fusion. Several types of molecules are involved in the coordination of suture fusion during growth and development. During postnatal development, the regulation of suture fusion shifts to the osteogenic front, whereas signals from the dura mater are important for suture development before birth. During fusion, growth-related factors involved in bone formation are present in the suture matrix. Others are downregulated. Furthermore, cranial suture fusion is influenced by biomechanical forces on the skull, particularly masticatory pressure on the palate and face. This multiple effect on suture growth and development highlights the difficulty of using suture fusion for age estimation. Therefore, when other methods of age estimation from the cranial suture are not available, the use of palatal suture fusion is best combined with other age estimation criteria. Some researchers have highlighted the complexity of

biomechanical influences, with results finding statistically significant differences in the relationship between culling rates and dental health in adulthood, which is related to chewing habits and activities.¹³

Other studies show that complex growth of the upper jaw develops almost equally in anteroposterior and latero-lateral directions until approximately 15 years in females and 17 years in males. Therefore, changes in anteroposterior length provide a reasonable estimate of total growth. Indeed, there is sexual dimorphism, as the anteroposterior growth of the maxillary complex occurs mainly through the posterior transverse suture, which is active until the age of 13 in females and 15 in males. These results suggest that the growth of the maxillary complex is mainly related to the maxilla, whereas the lengths of the premaxillary and palatine bones are stable in both sexes after the age of nine years. The ossification of the midpalatal suture can be measured in a plane that is parallel to the durum palate or perpendicular to it. Ossification increases with age in the male maxilla. However, significant ossification is rare during adolescence and may not increase significantly until after the age of 20 years.¹⁸

Sex differences influence the timing of closure of the palatal suture; in general, males show more obliteration than females at all ages, although the prediction of age is more accurate in females than in males. Therefore, sex should be considered when using this suture as an indicator of age. Although suture closure appears to be more progressive in men than in women at a given age, women provide more accurate age predictions than men. Women were 59% accurate in predicting 10 years. Men were only 34% accurate.^{4,16}

Although the Mann method has limited applicability in forensic contexts, it is useful in providing a lower limit for overall age estimation. Maxillary sutures in hard ceilings are more reliable than other sutures but should be used cautiously. Although closure of the palatal suture does not provide a definitive age estimate for an individual, it can provide additional information for an approximate age range, particularly in older individuals—where other methods become less effective. For example, people over the age of 60 show a loss of at least two of the four palatal sutures. Research needs to be conducted to improve the reliability of the palatine suture closure method for use in forensic odontological casework.⁴

The Mann method is one of the age estimation methods suitable for burn victims, especially when the condition of the teeth cannot be analyzed due to severe damage. In this case, this method became the main method for age estimation in forensic odontology, as the teeth were severely damaged and could not be analyzed. As a result, based on the Mann method and the closure of the sutures, we can estimate the victim's age to be over 50 years. The limitation of this case report is that there is no other part of the body, such as teeth, that we can use to compare the age of the victim.

ACKNOWLEDGMENTS

The authors thank to Forensic Science and Medicolegal Department of Dr. Cipto Mangunkusumo Hospital and the Universitas Indonesia.

REFERENCES

- de Boer HH, Blau S, Delabarde T, Hackman L. The role of forensic anthropology in disaster victim identification (DVI): recent developments and future prospects. *Forensic Sci Res.* 2019; 4(4): 303–15.
- de Boer HH, Roberts J, Delabarde T, Mundorff AZ, Blau S. Disaster victim identification operations with fragmented, burnt, or commingled remains: experience-based recommendations. *Forensic Sci Res.* 2020; 5(3): 191–201.
- Gilbert SW, Butry DT. Identifying vulnerable populations to death and injuries from residential fires. *Inj Prev.* 2018; 24(5): 358–64.
- Adserias-Garriga J, Wilson-Taylor R. Skeletal age estimation in adults. In: Age estimation: A multidisciplinary approach. Academic Press; 2019. p. 55–73.
- Prakoeswa BFWR, Kurniawan A, Chusida A, Rizky BN, Darmawan AI, Aisyah AKN, Alias A. Using the Demirjian method for estimating the dental age of children in Surabaya, Indonesia. *Dent J.* 2023; 56(2): 87–91.
- Anjani RCS, Artaria MD, Singuwan P, Arunoraj J, Mahakkanukrauh P. Biological identification of skulls in Indonesian and Thai populations: ancestry estimation, sex determination, stature estimation, and age estimation. *Int J Morphol.* 2024; 42(1): 137–46.
- Carazo MS. Application of the Maxillary suture obliteration method for estimation of the age at death of prisoners in the Valencian Francoist Prison. *Bioarchaeology Balk.* 2017; : 85–90.
- Mann RW, Jantz RL, Bass WM, Willey PS. Maxillary suture obliteration: a visual method for estimating skeletal age. *J Forensic Sci.* 1991; 36(3): 781–91.
- Cappella A, Cummaudo M, Arrigoni E, Collini F, Cattaneo C. The issue of age estimation in a modern skeletal population: Are even the more modern current aging methods satisfactory for the elderly? *J Forensic Sci.* 2017; 62(1): 12–7.
- Savoldi F, Xu B, Tsoi JKH, Paganelli C, Matinlinna JP. Anatomical and mechanical properties of swine midpalatal suture in the premaxillary, maxillary, and palatine region. *Sci Rep.* 2018; 8(1): 7073.
- Mann RW. Maxillary suture obliteration: a method for estimating skeletal age. University of Tennessee, Knoxville; 1987. p. 1–93.
- Ruengdit S, Prasitwattanaseree S, Mekjaidee K, Sinthubua A, Mahakkanukrauh P. Age estimation approaches using cranial suture closure: A validation study on a Thai population. *J Forensic Leg Med.* 2018; 53: 79–86.
- Hens SM, Godde K. New approaches to age estimation using palatal suture fusion. *J Forensic Sci.* 2020; 65(5): 1406–15.
- Barbosa NMV, Castro AC de, Conti F, Capelozza-Filho L, Almeida-Pedrin RR de, Cardoso M de A. Reliability and reproducibility of the method of assessment of midpalatal suture maturation: A tomographic study. *Angle Orthod.* 2019; 89(1): 71–7.
- Bugelli V, Papi L, Fornaro S, Stefanelli F, Chericoni S, Giusiani M, Vanin S, Campobasso CP. Entomotoxicology in burnt bodies: a case of maternal filicide-suicide by fire. *Int J Legal Med.* 2017; 131(5): 1299–306.
- Ruengdit S, Troy Case D, Mahakkanukrauh P. Cranial suture closure as an age indicator: a review. *Forensic Sci Int.* 2020; 307: 110111.
- Beauthier J, Lefevre P, Meunier M, Orban R, Polet C, Werquin J, Quatrehomme G. Palatine sutures as age indicator: a controlled study in the elderly. *J Forensic Sci.* 2010; 55(1): 153–8.
- Savoldi F, Wong KK, Yeung AWK, Tsoi JKH, Gu M, Bornstein MM. Midpalatal suture maturation staging using cone beam computed tomography in patients aged between 9 to 21 years. *Sci Rep.* 2022; 12(1): 4318.

Palatine suture obliteration method for age estimates of burn victims with minimal tooth remains: a case report

ORIGINALITY REPORT

13%

SIMILARITY INDEX

8%

INTERNET SOURCES

8%

PUBLICATIONS

4%

STUDENT PAPERS

PRIMARY SOURCES

1

www.ncbi.nlm.nih.gov

Internet Source

2%

2

www.researchgate.net

Internet Source

2%

3

Annalisa Cappella, Marco Cummaudo, Elena Arrigoni, Federica Collini, Cristina Cattaneo.

"The Issue of Age Estimation in a Modern Skeletal Population: Are Even the More Modern Current Aging Methods Satisfactory for the Elderly?," Journal of Forensic Sciences, 2017

Publication

1%

4

Fabio Savoldi, Bing Xu, James K. H. Tsoi, Corrado Paganelli, Jukka P. Matinlinna.

"Anatomical and mechanical properties of swine midpalatal suture in the premaxillary, maxillary, and palatine region", Scientific Reports, 2018

Publication

1%

5

www.tandfonline.com

Internet Source

1%

6

Submitted to University of Wisconsin System

Student Paper

1%

7

Submitted to CUNY, John Jay College of Criminal Justice

Student Paper

<1%

8

Submitted to University of Kent at Canterbury

Student Paper

<1%

9	talus.matrix.msu.edu Internet Source	<1 %
10	Katalin Wolff, E. Hadadi, Z. Vas. "A novel multidisciplinary approach toward a better understanding of cranial suture closure: The first evidence of genetic effects in adulthood", <i>American Journal of Human Biology</i> , 2013 Publication	<1 %
11	Submitted to Lindenwood University Student Paper	<1 %
12	Paulina Gutiérrez-Tiznado, Sandra López-Lázaro, Gabriel M. Fonseca. "Age estimation by evaluation of obliteration of the palatine sutures: a scoping review", <i>Forensic Science, Medicine and Pathology</i> , 2023 Publication	<1 %
13	Submitted to University College London Student Paper	<1 %
14	Submitted to Higher Education Commission Pakistan Student Paper	<1 %
15	meridian.allenpress.com Internet Source	<1 %
16	www.stitcher.com Internet Source	<1 %
17	www.sulabhenviis.nic.in Internet Source	<1 %
18	Fernanda Macedo, Maria Eduarda Stefanel, Adriano Sakurada, Débora Moreira, José Luiz Cintra Junqueira, Ademir Franco. "Skull joints assessed via CT for age estimation—a systematic review", <i>Dentomaxillofacial Radiology</i> , 2025 Publication	<1 %

19	Submitted to Pennsylvania State System of Higher Education	<1 %
Student Paper		

20	oamjms.eu	<1 %
Internet Source		

21	www.sciepublish.com	<1 %
Internet Source		

22	Ye Xue, Fei Fan, Meng Liu, Shuai Luo et al. "Age estimation from median palatine suture using computed tomography reconstructed 3D images: a comparison of Northern and Southwestern Chinese populations", International Journal of Legal Medicine, 2024	<1 %
Publication		

Exclude quotes	On	Exclude matches	Off
Exclude bibliography	On		

Palatine suture obliteration method for age estimates of burn victims with minimal tooth remains: a case report

GRADEMARK REPORT

FINAL GRADE

GENERAL COMMENTS

/0

PAGE 1

PAGE 2

PAGE 3

PAGE 4

PAGE 5

PAGE 6

PAGE 7